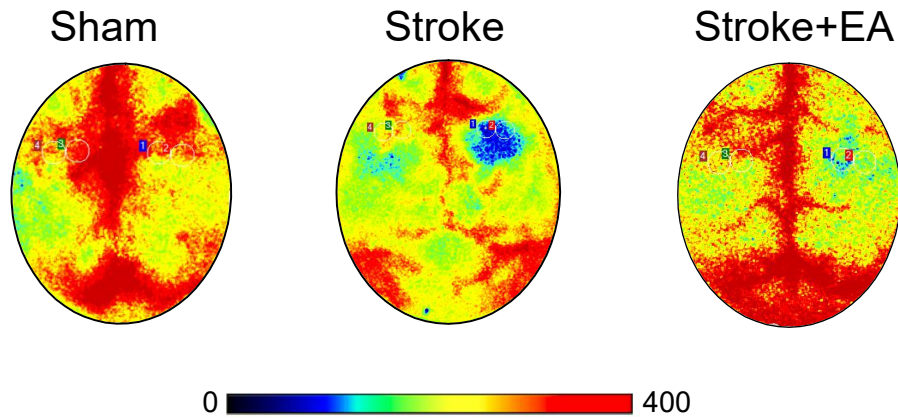


Additional Figures

Additional Figure 1 Laser speckle blood flow imaging showed blood perfusion in the entire brain was decreased after stroke, while rescued by EA.

Sample images showing the blood perfusion in the sham (left), stroke (middle), and stroke + EA groups (right). It shows the low level of blood perfusion in the ipsilateral M1 after unilateral ischemia (blue indicates low blood perfusion). The blood perfusion recovery after EA treatment was represented. EA: Electroacupuncture; M1: primary motor cortex; S1: primary somatosensory cortex.